

CASE REPORT

Open Access



The misdiagnose and treatment of a concealed kind of supernumerary nostril: a case report and review

Caiyun Li^{1†}, Qianqian Pang^{1†}, Haiying Zhou², Ahmad Alhaskawi², Yanzhao Dong² and Hui Lu^{2*} 

Abstract

Background: Supernumerary Nostril, also called triple nostrils or accessory nostril, is a rare congenital nasal malformation.

Case presentation: We report one conceal case of supernumerary nostril in a 19-years-old men which is misdiagnosed to a simple small nasal skin pit. Ordinary surgical excision led to recurrent infection of the lesion postoperatively, and was eventually required secondary surgery and the lesion was finally confirmed by pathological biopsy as a trinasal nostrils.

Conclusions: Through this case, we stress the essential role in differential diagnosis, confirming the diagnosis and seeking for better solutions.

Level of Evidence V

Keywords: Congenital nasal malformation, Supernumerary nostril, Nasal sinus, Nasal dermal sinus, Misdiagnosis

Background

Supernumerary nostril is a rare congenital defect, with approximately 60 related cases reported since Lindsay was first reported in 1906 [1]. In some reported cases, the patients appear to have an accessory nostril, either above or below the normal nostrils, which can be easily diagnosed. However, we report a misdiagnosed case of unobvious congenital supernumerary nostril, which to our knowledge, no similar cases have been reported.

Case report

A 19-year-old man came to our department because of a small pit on the nasal dorsum which made him look different (Fig. 1). The small pit ranged 3 mm in diameter was found when he was born and had not increase in size significantly, nor discovered fluid or pus but a few sebaceous like secretion. There are no similar diseases in the family. It was diagnosed as a simple skin pit malformation. So, we decided to remove the pit. During the operation of the skin pit resection, we found that there was a sinus paralleling to the nasal dorsum which was about 2 cm in length (Fig. 2), but the patient refused further surgery and the incision was sutured as a palliative.

Within 1-year post surgery, the incision area was repeatedly infected with subcutaneous abscess. CT scan with contrast medium infused into the sinus showed that there was no obvious deformity in the nasal bone and skull base. The diameter of the sinus is about 3 mm wide and its depth is about 2 cm. And, the

[†]Caiyun Li and Qianqian Pang contributed equally to this work

*Correspondence: huilu@zju.edu.cn

² Department of Orthopedics, The First Affiliated Hospital, College of Medicine, Zhejiang University, # 79Qingchun Road, Zhejiang 310003 Hangzhou, People's Republic of China

Full list of author information is available at the end of the article



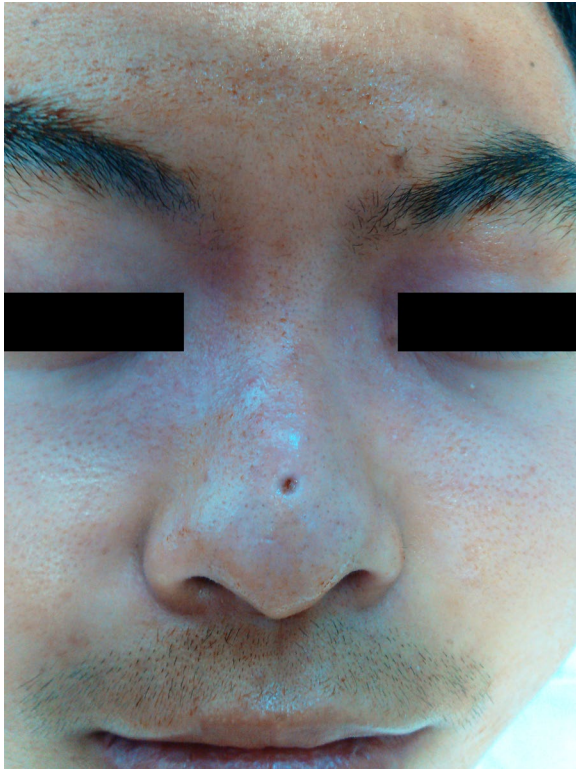


Fig. 1 Patient with a small pit on the nasal dorsum before the first operation

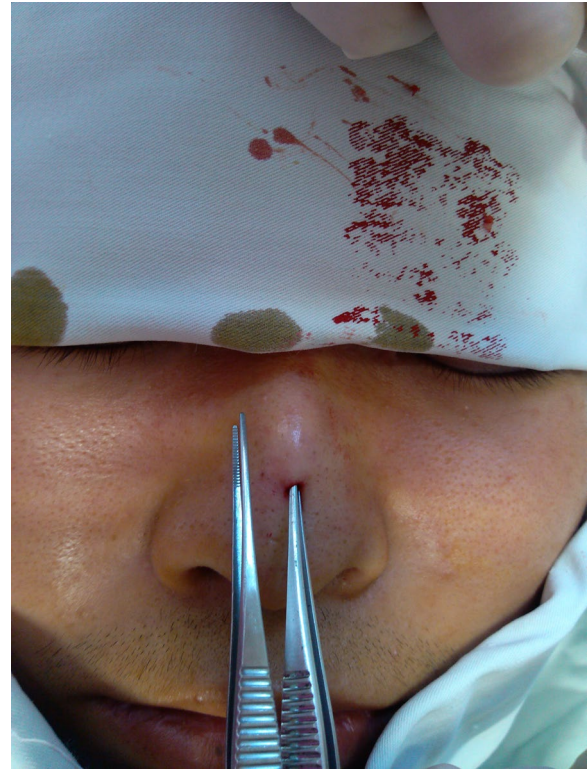

Fig. 2 There was a sinus paralleling to the nasal dorsum which was about 2 cm in length

sinus and the nasal cavity are not connected (Gif.1). We concluded with the diagnosis of a supernumerary nostril.

Design: The surgery was designed with an Inverted-V shaped incision on the columella and extended to the nasal cavity along the lower edge of the alar cartilage (Fig. 3). The skin was cut open, then dissected upward and separated the sinus between the skin and bone. We are able to see the mucosa or skin like structure in the sinus and the thick, black nose hair evenly distributed. We verify the nasal cavity is not connected to the sinus, and we removed the accessory sinus nostril completely. The size of the accessory mass is about 2 cm × 3 mm (Fig. 4); and the excess composite tissue is trimmed. Then the skin incision was sutured and bandaged with pressure. Histology showed hairy root, hair follicles and rich sebaceous glands (Fig. 5).

The patient's condition was generally good after the surgery, and the suture was removed on the 7th day, the incision was recovered well, and appearance of the nose was satisfying after half a year (Fig. 6), and even better 4 years later (Fig. 7).

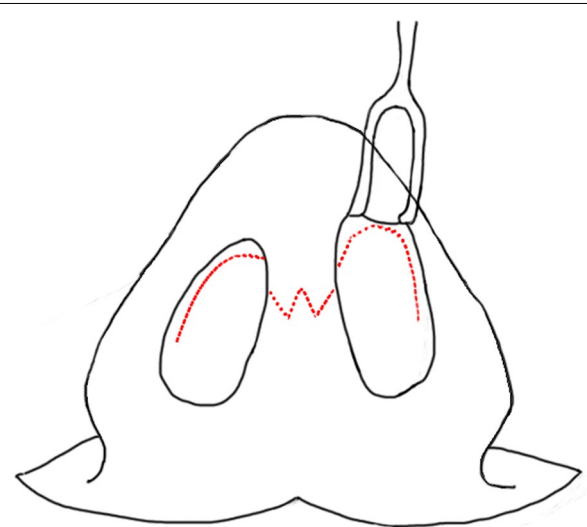


Fig. 3 An Inverted-V shaped incision was designed

Discussion

This is an interesting case because the accessory nostril was observed only as a small pit on the nasal dorsum skin which differs in its appearance from all the other

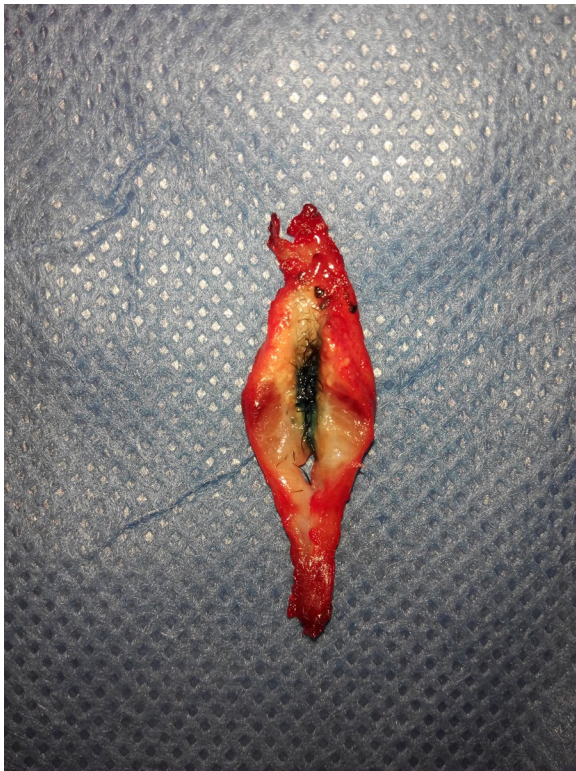

Fig. 4 The showing of the removed sinus cutted: open:methylene blue show it was a blind sinus and there were thick rhinoliths

previously reported cases. Although, it was successfully treated finally. We still need to know about the multiple appearances of the supernumerary nostril for better treatment.

Supernumerary nostril is a rare congenital defect that defined as the presence of additional nostrils when a pair of normal nostrils already exist, and may be manifested as asymmetric redundancy and differ from complete nasal duplication in horizontal or vertical [2]. The exact etiology is not known, but it is currently accepted to be caused by a fissure of the nasal process during the aberrant embryonic development [3].

Some of the cases are one of the manifestations of the multiple malformations, while others are simple multiple nostrils that show the presence of distinct cavities or localized bulges, totally different from the appearance of a normal nose [4–6]. None of these reports is similar to the case we presented in this article, given that the accessory nostril was observed only as a small pit on the nasal dorsum skin and is not easily detectable. We can infer from this case that differential diagnosis and timely treatment of this disease values a lot.

First of all, pay attention to the personal history of patient, along with the symptom of the disease, as many of the cases are reported to be associated with multiple congenital malformations. Second, imaging examinations such as CT scan are necessary, helping us to exclude the presence of other problems [7]. And if the supernumerary nostril is a clear orifice, it may appear in cross-sectional imaging as a redundant outward projection of the nasal wing, connected to the adjacent nostril by air [7].

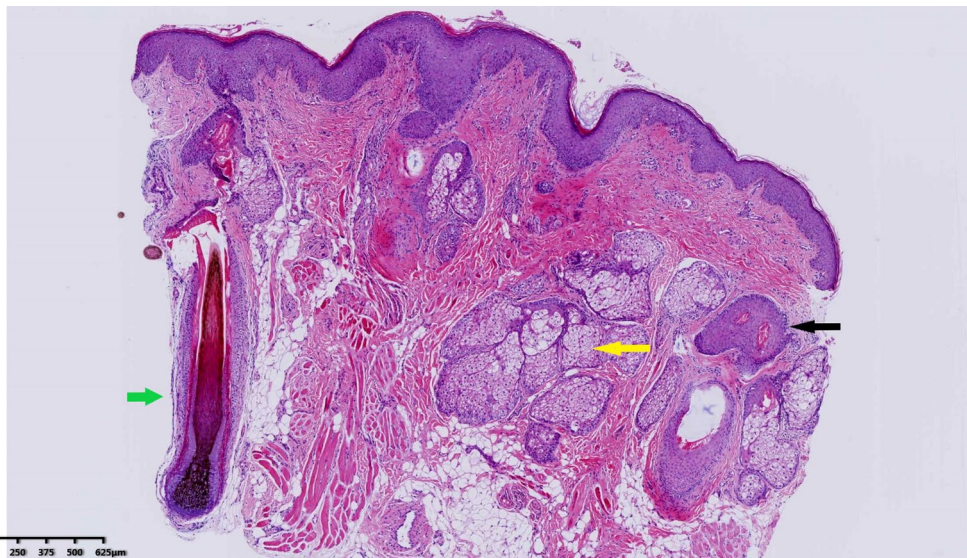


Fig. 5 Histology showed hairy root (green arrow), hair follicles (black arrow) and rich sebaceous glands (yellow arrow)

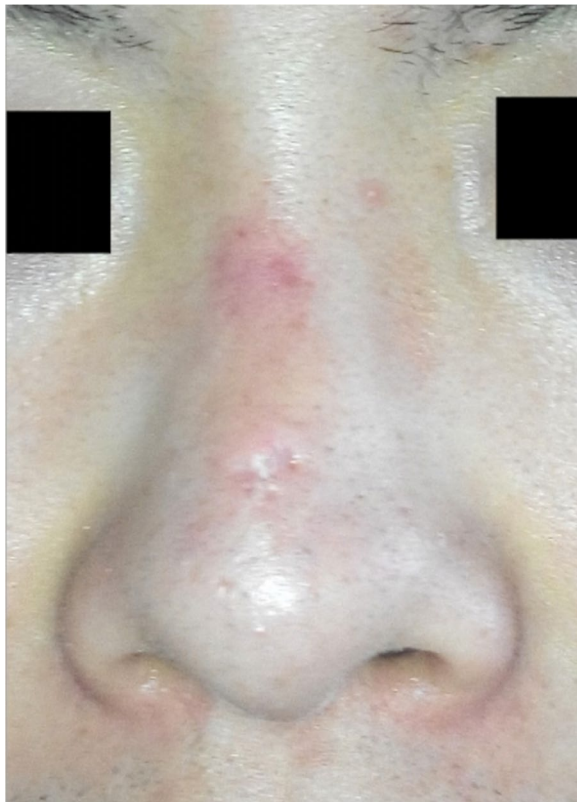

Fig. 6 Postoperative picture of the patient(6 months)

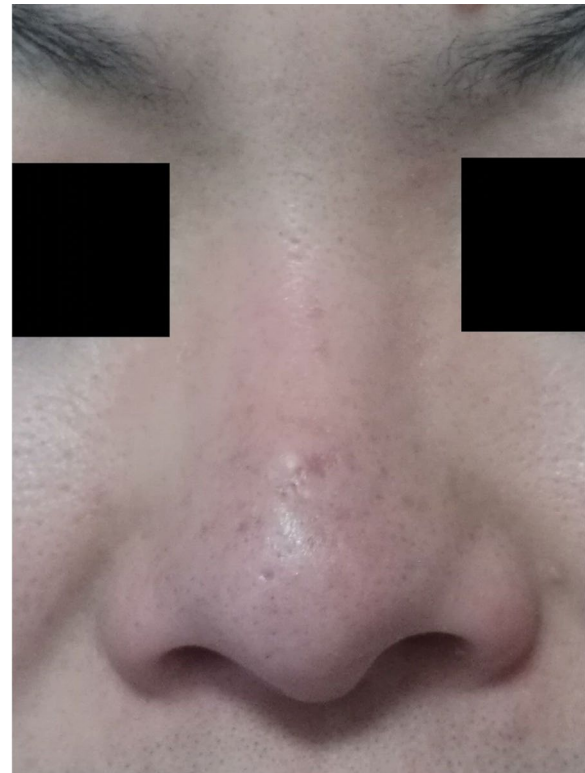

Fig. 7 Postoperative picture of the patient (4 years). CT showing the extent of the sinus with in it

This case actually belongs to congenital nasal malformation, which must be distinguished from encephalocele, nasal dermal sinus, nasolacrimal duct obstruction, mid facial cleft and proboscis lateralis [8, 9]. The diagnostic points are the following: (1) Mostly located above the nosewing, which appears like accessory nostrils, with rhinothrix and occasionally white mucus excretions, without breathing; (2) The abnormal nostril is made of skin soft tissue without cartilage, and is not connected to normal nostrils; (3) Auxiliary examination proves that it does not communicate with the nasopharynx. The end of the small hole is blind, or connected with the ethmoid sinus or maxillary sinus, which often accompanied by nasosinusitis; (4) Histology reveals hair follicles, hairy roots and sebaceous glands, but no olfactory cells are found.

Due to its rarity, the exact timing of the intervention and the treatment modality have reached no consensus. Mostly, the literature favors early surgery to ameliorate the medical risks it may pose such as psychosocial disorders or any derangement to the nasal [10, 11]. In our case, although there was no obvious malformation as described in previous literature, it still affected the patient's appearance to some extent. Meanwhile after closing the sinus opening palliatively, the recurrent

postoperative inflammation occurred and made it important to remove the lesion completely by surgery. In our case, although there were no obvious aesthetic defects, recurrent focal infections and unexplained discharge did bring discomfort to the patient's life. Therefore surgery is a good option. The traditional treatment option is to remove the nasal tract and correct the ala [11]. The challenge of reconstruction is to restore nasal airflow while achieving nasal symmetry. In our case, the redundant nostril was not adjacent to the normal nosewing or normal nostrils and did not inappropriately affect the normal nostrils either in appearance or function. Therefore, fortunately, for this patient, a complete excision of the nasal tract was sufficient. And we opted not to remove all the excess nostril tissue and to excise only the nasal tract, for the skin can be used to cover the soft tissue defects caused by the excess nostril resection and lead to minimal deformation.

Conclusions

In this study, we presented a concealed case of supernumerary nostril.

manifested as a small pit located on the nasal dorsum in a male adult. We made final diagnosis based on the

clinical appearance, physical examination and histological features of the supernumerary nostrils. As described above, the cause and development of this disease is still unclear. However, we advocated early surgical treatment and suggested to handle similar situations with the columellar Inverted-V incisions. Early treatment is recommended to prevent any possible alar or nostrils deformity, as well as avoiding psychological problems.

Acknowledgements

Not applicable.

Author contributions

HL designed the study, CYL and QQP performed data collection, HYZ and AA analyzed the results, YZD drafted the manuscript. All authors read and approved the final manuscript.

Funding

The study was funded by the Zhejiang Provincial Natural Science Foundation (Grant Number LS21H060001). The funding bodies had no role in the design of the study; in collection, analysis, and interpretation of data; and in drafting the manuscript.

Data availability

Not applicable.

Declarations

Ethics approval and consent to participate

All procedures conducted in research involving human participants are in accordance with the ethical standards of the institution and national research committee. Informed consent was obtained from the patient to publish the case and accompanying figures.

Consent for publication

Written informed consent was obtained from the patient for publication of this Case report and any accompanying images. A copy of the written consent is available for review by the Editor of this journal.

Competing interests

The authors declare no conflicts of interest.

Author details

¹Department of Plastic Surgery, The First Affiliated Hospital, College of Medicine, Zhejiang University, # 79Qingchun Road, Zhejiang 310003 Hangzhou, People's Republic of China. ²Department of Orthopedics, The First Affiliated Hospital, College of Medicine, Zhejiang University, # 79Qingchun Road, Zhejiang 310003 Hangzhou, People's Republic of China.

Received: 21 November 2021 Accepted: 8 June 2022

Published online: 13 June 2022

References

- Shen C, Shetye PR, Flores RL. Nasal duplication: a review of literature and case report. *Cleft Palate-Craniofacial J*. 2021;58(5):628–36. <https://doi.org/10.1177/1055665620962674>.
- Zbar RIRS, Ghimire P. Repair of congenital nasal anomalies involving redundancy of structures. *Cleft Palate Craniofac J*. 2003;40(2):214–7. https://doi.org/10.1597/1545-1569_2003_040_0214_rocnai_2.0.co_2.
- Aslanabadi Saeid D, Hamid Z, Sina, et al. Supernumerary nostril together with esophageal atresia, imperforate anus and patent ductus arteriosus: a case report and review of the literature. *Pediatr Surg Int*. 2009;25(5):433–6. <https://doi.org/10.1007/s00383-009-2351-9>.
- Shaye DA, Tibesar RJ. Repair of the supernumerary nostril. *J Craniofac Surg*. 2014;25(3):978–9. <https://doi.org/10.1097/SCS.0000000000000549>.
- Saiga A, Mitsukawa N. Case of supernumerary nostril. *J Plast Reconstr Aesthet Surg*. 2013;66(1):126–8. <https://doi.org/10.1016/j.bjps.2012.05.014>.
- Umeda TLH, Ohara H. Supernumerary nostrils associated with cleft lip and palate. *Br J Plast Surg*. 1996;49(7):499–500.
- Ginat DT, Robson CD. Diagnostic imaging features of congenital nose and nasal cavity lesions. *Clin Neuroradiol*. 2015;25(1):3–11. <https://doi.org/10.1007/s00062-014-0323-5>.
- Nakamura KOT. A case of supernumerary nostril. *Plast Reconstr Surg*. 1987;80:3.
- Kira TS. Nasal dermal sinus associated with a dumbbell-shaped dermoid: A Case Report. *J Neurol Surg Rep*. 2016. <https://doi.org/10.1055/s-0036-1584525>.
- Alqabbani AA, Alateeq MF, Alshalaan Z. Isolated congenital supernumerary nostril in an adult patient. *Ear Nose Throat J* 2020;3:2.
- Franco D, Medeiros J, Faveret P, et al. Supernumerary nostril: case report and review of the literature. *J Plast Reconstr Aesthetic Surg*. 2008;61(4):442–6. <https://doi.org/10.1016/j.bjps.2006.04.007>.

Publisher's Note

Springer Nature remains neutral with regard to jurisdictional claims in published maps and institutional affiliations.

Ready to submit your research? Choose BMC and benefit from:

- fast, convenient online submission
- thorough peer review by experienced researchers in your field
- rapid publication on acceptance
- support for research data, including large and complex data types
- gold Open Access which fosters wider collaboration and increased citations
- maximum visibility for your research: over 100M website views per year

At BMC, research is always in progress.

Learn more biomedcentral.com/submissions

