

RESEARCH

Open Access



# A combination of the K-L and S-P approaches for treating acetabular posterior wall fractures accompanied by femoral head fractures with open reduction and internal fixation

Shichao Lian<sup>1,2</sup> , Zhong Yang<sup>3</sup> , Zongliang Hu<sup>1</sup>  and Weidong Mu<sup>1\*</sup> 

## Abstract

**Background:** In clinical practice, acetabular posterior wall fracture combined with femoral head fracture is rare. However, with the increasing number of engineering and traffic accidents, such fractures, have increased significantly in recent years. This paper aims to explore the clinical efficiency of the Kocher-Langenbeck (K-L) and Smith-Petersen (S-P) combined approaches for open reduction and internal fixation (ORIF) of acetabular posterior wall fractures accompanied by femoral head fractures (Pipkin type IV fractures).

**Methods:** A retrospective study was conducted on 8 patients who underwent open reduction and internal fixation (ORIF) of Pipkin type IV fractures through the K-L combined with S-P approach in our hospital from January 2015 to January 2020. All 8 patients were successfully operated on without serious complications, such as important blood vessel and nerve damage, with an operation time of  $143.8 \pm 44.38$  min and intraoperative blood loss of  $225 \pm 70.71$  ml. Perioperative data were recorded. The Harris score was used to evaluate the clinical effect. Fracture reduction quality was evaluated according to the Matta radiological standard. The grade of ectopic ossification was evaluated by the Brooker grading method, and the stage of femoral head necrosis was evaluated by Ficat-Arlet staging.

**Results:** The Harris score increased significantly from  $57.38 \pm 4.779$  at 3 months, to  $76.13 \pm 3.682$  at 6 months,  $88.25 \pm 3.495$  at 12 months, and  $92.13 \pm 2.232$  at 36 months postoperatively. After statistical analysis, compared with the previous observation time point, the data comparison differences between the groups were statistically significant. ( $P < 0.001$ ,  $P < 0.001$ ,  $P < 0.05$ ). By the time of the latest follow-up, 6 of the 8 patients had recovered to the level of pre-injury sports capacity. In contrast, the other 2 patients remained below the level of pre-injury sports capacity. In terms of imaging evaluation, the quality of fracture reduction on radiographs was graded as excellent in 6 patients and good in 2 patients according to Matta's criteria. At the last follow-up, no heterotopic ossification or femoral head necrosis was found in of all the images. In addition, the hip joint space was normal in 6 cases, mildly narrowed in 1 case, and clearly narrowed in 1 case.

\*Correspondence: sds1mwd@126.com

<sup>1</sup> Department of Traumatic Orthopedics, Shandong Provincial Hospital, Shandong University, No. 324 Jingwu Weiqi Road, Jinan 250012, Shandong, China

Full list of author information is available at the end of the article



**Conclusions:** The K-L combined with S-P approach provides effective exposure for the reduction and fixation of Pipkin type IV fractures and achieves satisfactory clinical outcomes.

**Keywords:** Pipkin type IV fracture, Acetabular posterior wall fracture, Femoral head fracture, Surgical approach, K-L approach combined with S-P approach

## Background

In clinical practice, acetabular posterior wall fracture combined with femoral head fracture is rare. Even the dislocation of the hip joint causing femoral head fracture accounts for only 5–15% [1]. However, in recent years, with the increasing number of engineering and traffic accidents, such fractures have increased significantly. They are caused mostly by high-energy injuries, such as falling injuries and traffic accident injuries [2]. For acetabular fracture with femoral head fracture, restoring the normal anatomical morphology of the hip joint and obtaining good clinical function while minimizing the occurrence of complications such as femoral head necrosis, malunion and traumatic arthritis of the hip joint is still a major problem for orthopedic doctors. In 1951, Thompson [3] proposed the classification of posterior dislocation of the hip joint and introduced femoral head fracture combined with posterior dislocation of the hip joint as an independent subtype (Thompson Epstein V type) for the first time. In 1957, Pipkin [1] further subdivided the type V fracture in the Thompson Epstein classification into four subtypes, so femoral head fracture combined with posterior dislocation of the hip joint is also called Pipkin fracture. In Pipkin's classification, besides accompanied by posterior dislocation of the hip joint, type I is the femoral head fracture caudad to fovea capitis, type II is the femoral head fracture cephalad to fovea capitis, and type III is type I or II fracture with associated femoral neck fracture. Pipkin type IV is combined with acetabular fractures based on the anterior 3 types, and it's also the main difference between it and other 3 types, usually acetabular posterior wall fractures. The typical injury mechanism of Pipkin type IV fracture is that in the state of hip and knee flexions, great violence is transmitted to the femoral head through the femur. The femoral head violently strikes the acetabulum, resulting in the fracture of the femoral head and acetabulum, usually combined with posterior dislocation of the hip joint [4]. The causes of Pipkin type IV fracture's refractory is the complication as well as sequela more after injury and its operative difficulty. Compared with type I, II and III Pipkin fractures, Pipkin type IV fracture is faced with the problems of not only protecting the blood supply of femoral head, but also dealing with acetabular fracture and protecting hip joint capsule. Especially the fracture of acetabular posterior wall, is easy to cause the

instability of hip joint. Therefore, in addition to protecting the blood supply of the femoral head and effectively reducing and fixing the fractures of femoral head and acetabulum, many factors such as repairing the hip joint capsule and avoiding excessive peeling of the joint capsule should also be considered. Therefore, the difficulty of operation increases significantly, and a single incision is difficult to meet the above treatment requirements at the same time. At present, most orthopedic scholars have studied more types I, II, and III Pipkin fractures. However, there are few studies and reports on the rare type IV Pipkin fractures. This paper aims to retrospectively explore the clinical effect of K-L combined with the S-P approach in treating posterior acetabular wall combined with femoral head fracture (Pipkin type IV fracture).

## Methods

### Patients

There were 8 patients in this group, all had Pipkin IV fractures, and the fracture lines of the femoral head were located below the central fovea. All patients were male, aged from 24 to 53 years, with an average of  $41.38 \pm 11.35$  years. There were 6 cases of falling injury and 2 traffic accident injury cases. Among them, 3 cases were complicated with sciatic nerve injury (Table 1).

This study was approved by the Shandong Provincial Hospital Medical Science Research Ethics Committee. Informed consent was obtained from all patients. All methods performed in this study were in accordance with the Declaration of Helsinki.

### Surgical technique

Manual reduction of hip dislocation and bone traction of the tibial tubercle were performed in emergency situations. Improve relevant auxiliary examination and consultation of relevant departments before operation (Fig. 1). Surgical treatment was performed 4–7 days after injury, with an average of  $4.875 \pm 1.126$  days.

The patient underwent general anesthesia with endotracheal intubation, took the floating position, and used the K-L approach behind the hip joint first. The apex of the greater trochanter was taken as the center, and an incision with a length of approximately 10 cm was made to expose the joint capsule (Fig. 2A). The posterior wall fracture of the acetabulum was displaced and partially comminuted. The residual joint capsule was protected,

**Table 1** Demographic data of eight patients with Pipkin type IV fractures undergoing the K-L approach combined with the S-P approach for ORIF

Category (n = 8)	Mean ± SD/ n(%)
Age	41.38 ± 11.35
Preoperative time (day)	4.875 ± 1.126
Intraoperative bleeding (ml)	225.0 ± 70.71
Operation time (min)	143.8 ± 44.38
Intraoperative bleeding	
Red blood cell (U)	2.75 ± 1.035
Plasma (ml)	200.0 ± 0.00
Sex	
Male	8 (100.0%)
Female	0 (0.0%)
Cause of injury	
Traffic accident injury	2 (25.0%)
Falling injury	6 (75.0%)
Combined with sciatic nerve injury	
Yes	3 (37.5%)
No	5 (62.5%)

K-L Kocher-Langenbeck approach, S-P Smith-Petersen approach, ORIF open reduction and internal fixation

the posterior wall fracture block was reduced, the flatness of the joint surface was restored, and plate-screw was used to fix the fracture block. When the fracture block is too small, use suture anchor to fix it. Due to the various shapes of fracture blocks, there is no unified standard for the selection of internal fixation. The aim is to preserve the bone mass of the posterior acetabular wall as much as possible to maintain the stability of the hip joint (Fig. 2B). In patients with sciatic nerve injury, the sciatic nerve was released after hip joint reduction. Traction and external rotation of the affected limb revealed the fracture of the femoral head, showing that the free rotation and reduction of the fracture block of the femoral head were difficult. The procedures involve the following: taking the S-P approach in front of the hip joint (Fig. 2C), using a limited open distal part, entering in the gap between the fascia lata and the sartorius muscle, pulling off the straight femoral muscle, exposing and partially cutting the articular capsule, abducting and rotating the affected limb, exposing the femoral head fracture, reducing the fracture and fixing it with a countersunk nail. When the position of the fracture line of the femoral head in some patients is lower and it is difficult to place the implant, the towel forceps should be temporarily and percutaneously fixed under fluoroscopy. Postoperative routine prevention of infection, heterotopic ossification, and deep venous thrombosis. Bone traction was continued for 4 weeks, with a weight of 3–5 kg. Quadriceps femoris

contraction and ankle extension and flexion exercises were performed on the 2nd day after the operation. Hip and knee extension and flexion exercises were performed on the 1st week, walking with partial weight by the aid of walking aids for 6–8 weeks and gradually walking with full weight after 3 months.

#### Evaluating indicator

Perioperative data were recorded. The Harris [5] score was used to evaluate the clinical effect. The quality of fracture reduction was evaluated according to the Matta [6] radiological standard, the ectopic ossification grade was evaluated by the Brooker [7] grading method, and the stage of femoral head necrosis was evaluated by Ficat-Arlet [8] staging.

#### Statistical analysis

SPSS 25.0 software was used for statistical analysis. The measurement data are expressed as  $\bar{x} \pm s$  (mean ± SD). The data at more than three times points and the pairwise comparison between them were analyzed by one-way ANOVA.  $P < 0.05$  indicates that the difference is statistically significant.

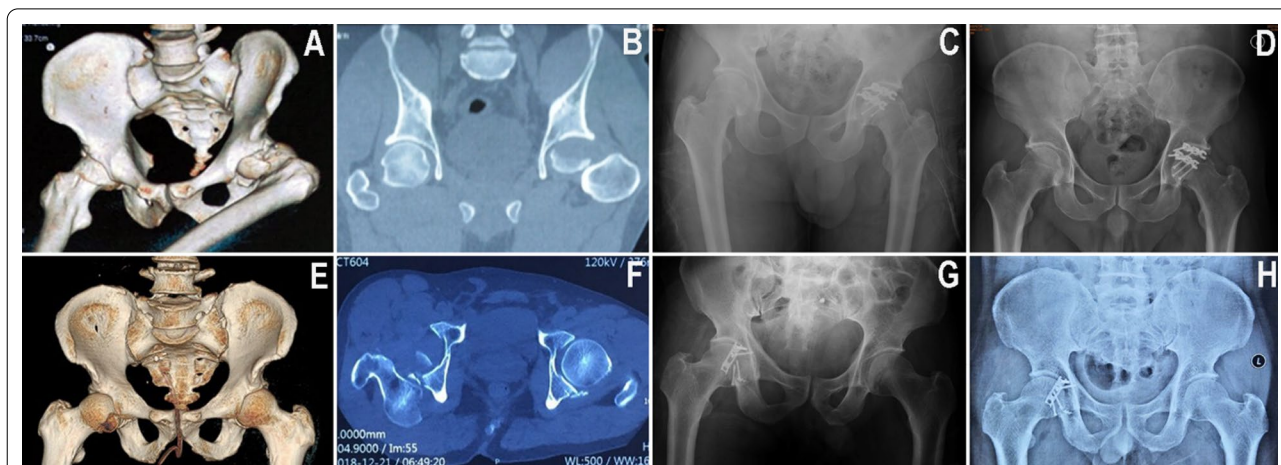
## Results

#### Clinical outcomes and complication management

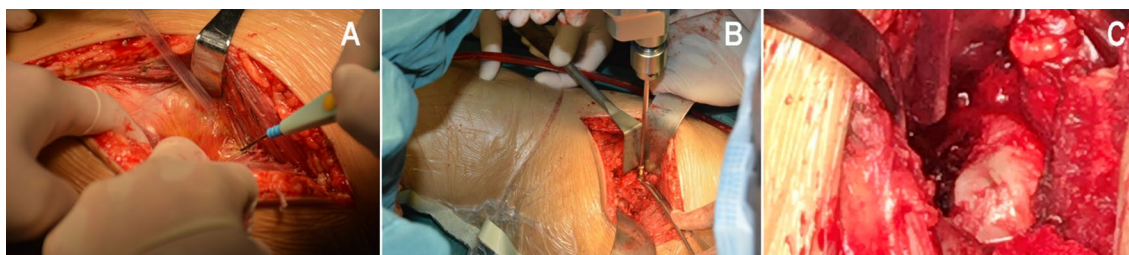
All patients completed the operation without serious complications, such as important blood vessels and nerve injury. The operation time was  $143.8 \pm 44.38$  min. The average amount of intraoperative bleeding was  $225 \pm 70.71$  ml. All incisions healed in Grade A without infection.

Up to the last follow-up, no complications, such as avascular necrosis of the femoral head, traumatic arthritis of the hip, fracture of internal fixation, loss of fracture reduction or fracture nonunion, occurred in all cases, and no patients needed reoperation.

All 8 patients were followed up for more than 36 months. Three patients who had sciatic nerve injury before the operation and showed a weakness of the ankle joint and toe dorsum were treated with mecobalamin and other nutritional nerve drugs. Their sciatic nerve injury symptoms gradually disappeared and returned to normal 6–12 weeks after the operation. All combined injuries were treated satisfactorily, and other fractures healed within 6 months after the operation. One patient had a common peroneal nerve injury before the operation, did not fully recover at the last follow-up, and had lower limb numbness and foot drooping. However, it did not affect the function of the hip joint, so it did not affect the hip functional evaluation. After the operation, nutritional nerve and rehabilitation treatment were continued for common peroneal nerve injury; the other 7



**Fig. 1** Typical case images. **A, B, E, F** Preoperative CT showed an acetabular posterior wall fracture and posterior dislocation of the hip. The fracture line of the left femoral head was located below the fovea. **C, G** X-ray examination immediately after the operation showed that the fracture was anatomically reduced, and the position of internal fixation was good. **D, H** X-ray examination at follow-up 1 year after operation showed that the fracture healed, no femoral head necrosis occurred, and the hip joint space was normal



**Fig. 2** Main surgical steps of the K-L approach combined with the S-P approach for ORIF. **A** Posterior K-L approach. **B** Reduction and fixation of acetabular posterior wall fracture through the K-L approach. **C** Reduction and fixation of femoral head fracture through the S-P approach; K-L Kocher-Langenbeck approach, S-P Smith-Petersen approach, ORIF open reduction and internal fixation

patients recovered well in walking and labor ability. The Harris score increased significantly from  $57.38 \pm 4.779$  at 3 months to  $76.13 \pm 3.682$  at 6 months ( $P < 0.001$ ) and from  $88.25 \pm 3.495$  at 12 months to  $92.13 \pm 2.232$  at 36 months ( $P < 0.05$ ). At the last follow-up, of the 8 patients, 6 recovered to the preinjury motor ability level, and 2 still did not recover to the preinjury motor ability level. (Table 2; Fig. 3)

#### Image evaluation

According to the Matta evaluation standard, postoperative X-ray and CT showed that the quality of fracture reduction was excellent in 6 cases and good in 2 cases. According to the Brooker criteria, no ectopic ossification was found. At the last follow-up, 8 patients were rated as grade 0 according to Ficat-Arlet staging, and no femoral head necrosis was found. At the last follow-up, the hip joint space was normal in 6 cases, mild stenosis in 1

case and evident stenosis in 1 case (Table 3). Typical case images are shown in Fig. 1.

#### Discussion

The Pipkin classification is a commonly used classification system for femoral head fractures. Pipkin IV refers to the anterior 3 types combined with acetabular fractures. Asghar et al. [9] believe that this type of fracture needs surgery if it meets any of the following conditions: displacement of articular fracture surface  $> 1$  mm, instability after joint reduction, and fracture range of acetabular wall  $> 20\%$ ; Wang et al. [4] indicated that it is very important to restore the consistency and stability of the hip joint and remove small and comminuted intra-articular fractures as soon as possible. In addition, if the articular surface fracture of the femoral head cartilage is involved in the weight-bearing area, even small fracture blocks should be fixed and repaired. However, if

**Table 2** Harris scores of eight patients postoperatively

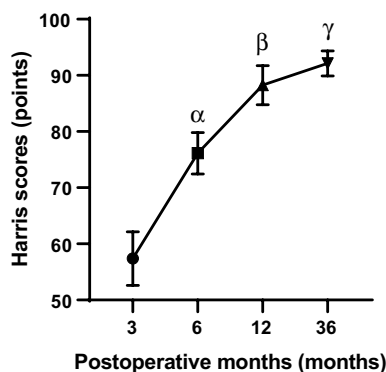
Category (n = 8)	Mean $\pm$ SD
3 months	57.38 $\pm$ 4.779
6 months	76.13 $\pm$ 3.682
12 months	88.25 $\pm$ 3.495
36 months	92.13 $\pm$ 2.232

**Table 3** Imaging evaluation of eight patients up to the last follow-up

Category (n = 8)	n (%)
Matta standard	
Excellent (A)	6 (75.0%)
Good (B)	2 (25.0%)
Joint space stenosis	
Normal	6 (75.0%)
Mild stenosis	1 (12.5.0%)
Obvious stenosis	1 (12.5.0%)
Brooker criteria	
Heterotopic ossification	0
Without heterotopic ossification	8 (100.0%)
Ficat–Arlet staging	
Femoral head necrosis	0
Without necrosis of femoral head	8 (100.0%)

the cartilage surface is defective or cannot be fixed, femoral head cartilage transplantation can reduce complications and obtain good results [10]. Ahmed et al. [11] A delayed reduction was associated with a higher rate of femoral head necrosis. Crock et al. [12] noted that avascular necrosis of the femoral head is an important factor affecting the prognosis of femoral head fracture, which is closely related to the injury of blood vessels supplying the femoral head, especially the medial circumflex femoral artery. Therefore, surgery is recommended as soon as possible. Some scholars reported that the operation should be performed within 3 days after injury. The author's clinical data showed that early traction closed reduction of the hip joint and operation within 7 days after the injury did not increase the incidence of femoral head necrosis.

In this study, a limited S-P incision combined with a posterior K-L incision was used to treat Pipkin type IV fractures. The procedures are as follows: take the posterior K-L approach first, expose but not free the sciatic nerve to protect the sciatic nerve to the greatest extent, fix the fracture of the posterior wall of the acetabulum, protect (or repair) the joint capsule attached to the posterior wall of the acetabulum, determine the fracture



**Fig. 3** Pairwise comparison of Harris scores during 12 to 36 months of follow-up. P( $\alpha$ ) < 0.001, 6 months versus 3 months, Harris scores improved significantly. P( $\beta$ ) < 0.001, 12 months versus 6 months, Harris scores improved significantly. P( $\gamma$ ) < 0.05, 36 months versus 12 months, the improvement in Harris scores was still statistically significant

position of the femoral head by rotating the lower limbs, and then take the distal part of the anterior S-P approach to fully expose and fix the fracture. Studies have shown that the distal part of the S-P approach is sufficient for the exposure and repair of femoral head fractures [13].

Key points and significance of operation: (1) Because only the distal part of the S-P approach is selected, the stable structure in front of the hip joint can be protected to the greatest extent, and the stripping of muscle tissue can be reduced to lower the risk of ectopic ossification; (2) When the femoral head fracture block is reduced and fixed through partial S-P incision, the “4” position of hip flexion and abduction can be maintained to expose the anterior and inferior fracture block when the joint capsule and synovial tissue connected to it are protected to the greatest extent; (3) The partial S-P incision for femoral head fracture fixation keeps away from the branch of femoral head blood supply mainly by the posterior medial femoral circumflex artery (MFCA). Thus, the purpose of reducing the risk of femoral head necrosis may be achieved. (4) The exposure of the anterior approach is clear, which is conducive to the reconstruction of the femoral head with bone graft and the matching and fixation of the head and acetabulum. (5) Studies have shown that the sub-branch of the MFCA penetrates the bone cartilage junction of the femoral head along the posterior upper part of the femoral neck to nourish the femoral head [14]. In the operation of the posterior approach, we tried to reduce the separation of the short external rotator muscle group, especially protecting the muscle group below the level of the external obturator muscle and the internal obturator muscle. Pay attention to the

M-shaped incision of the joint capsule and avoid disturbing the synovial branch of the MFCA when resetting the posterior wall of the acetabulum. At the same time, without posterior reduction of the femoral head fracture, it also reduces the possibility of interfering with the MFCA and protects the blood supply of the femoral head.

At present, the commonly used surgical approaches for the treatment of Pipkin type IV fractures mainly include the simple Kocher-Langenbeck (K-L) and surgical dislocation of the hip joint (Ganz) approaches. The simple K-L approach has a wide exposure range and can address fractures of the posterior acetabulum and femoral head simultaneously, which is favored by many scholars [15]. However, its surgical trauma is large, the incidence of complications such as vascular and nerve injury, avascular necrosis of the femoral head, and heterotopic ossification is high. It is difficult to reduce and fix under direct vision for anterior and inferior femoral head fracture blocks. Ganz et al. [16] proposed the improved K-L approach in 2001, also known as the surgical dislocation of hip joint (Ganz) approach. This approach can protect the blood supply of the femoral head fully expose the fracture site and achieve complete reduction and fixation. It has obtained good curative effects treating Pipkin type IV fractures [17, 18]. However, the operation of this approach is complex, the learning curve is long, and the surgical trauma is large. The incidence of postoperative femoral head necrosis is 12.5% [15], and the incidence of ectopic ossification is as high as 20–60% [19–21]. At the same time, because this approach requires femoral greater trochanter osteotomy, there is a risk of nonunion of the osteotomy block.

There are relatively few cases of Pipkin IV fracture treated by the combined anterior and posterior approach. Ellis et al. [22] have made relevant reports and agreed with its curative effect. Some scholars have conducted a 15-year follow-up study on a patient with a Pipkin IV fracture treated by a combined anterior and posterior approach and found that it can be used as an appropriate alternative method to treat Pipkin IV fractures under appropriate circumstances [23]. Although it has been reported that the modified Gibson approach has the advantage of treating two parts of fractures with one incision simultaneously [24], two approaches from one incision have the disadvantage of mutual interference due to their close distance and may aggravate the damage to soft tissue. In this study, the exposition of fractures through two incisions increased some trauma, but it did not increase the traction injury of soft tissue, and the exposition was clearer. Our latest research also shows that the

clinical effect of a direct anterior combined with direct posterior approach, which represents the idea of a combined approach, is also satisfactory.

Shortcomings of this study: To date, none of the patients in this group have serious surgical complications. However, the follow-up time of this study was 3~36 months, which is much shorter than the 81 months of Oransky et al. [25]. Therefore, there is still the possibility of complications such as avascular necrosis of the femoral head and traumatic arthritis of the hip in the later stage of this group, which needs further follow-up observation. Meanwhile, the number of Pipkin type IV fracture with femoral neck fracture cases is very small, and these cases was not included in this study. Brumback [26] proposed an improved classification system in 1987 and classified this kind of fracture as Brumback 3B fracture. Such cases maybe have a worse prognosis, and the treatment methods would be changed accordingly. Next, We will collect these cases separately for study, summarize appropriate treatment methods and reduce complications.

## Conclusions

Our retrospective study showed that the K-L approach combined with the limited S-P approach clearly expose the fracture site, conducive to anatomical reduction and strong fixation, and the clinical effect is satisfactory.

## Abbreviations

K-L: Kocher-Langenbeck approach; S-P: Smith-Petersen approach; ORIF: open reduction and internal fixation; MFCA: medial femoral circumflex artery.

## Supplementary information

The online version contains supplementary material available at <https://doi.org/10.1186/s12893-022-01597-w>.

**Additional file 1.** Imaging data.

**Additional file 2.** Statistical data.

**Additional file 3:** Table data.

## Acknowledgements

Not applicable.

## Author contributions

WDM made the study concept and design; ZLH conducted the acquisition of data; SCL wrote the main manuscript text; SCL prepared Figs. 1, 2 and 3 and ZY prepared Tables 1, 2 and 3; SCL made the data analysis; WDM and ZY supervised the study. All authors read and approved the manuscript.

## Funding

This study wasn't funded by any foundation or group.

## Availability of data and materials

All data generated or analysed during this study are included in this published article [and its Additional files 1, 2 and 3].

## Declarations

### Ethics approval and consent to participate

All methods were performed in accordance with the Declaration of Helsinki. The protocol used in this study was approved by Shandong Provincial Hospital Medical Science Research Ethics Committee. Informed consent was obtained from all patients by written document.

### Consent for publication

Not applicable.

### Competing interests

The authors declare that they have no competing interests.

### Author details

<sup>1</sup>Department of Traumatic Orthopedics, Shandong Provincial Hospital, Shandong University, No. 324 Jingwu Weiqi Road, Jinan 250012, Shandong, China.

<sup>2</sup>Zoucheng People's Hospital, No. 59 Qianquan Road, Zoucheng 273500, Shandong, China. <sup>3</sup>Binzhou Medical University, No. 346 Guanhai Road, Yantai 264003, Shandong, China.

Received: 10 February 2022 Accepted: 12 April 2022

Published online: 10 May 2022

## References

- Pipkin G. Treatment of grade IV fracture-dislocation of the hip. *J Bone Joint Surg Am.* 1957;39-A(5):1027–42.
- Romeo NM, Firoozabadi R. Classifications in brief: the pipkin classification of femoral head fractures. *Clin Orthop Relat Res.* 2018;476(5):1114–9.
- Thompson VP, Epstein HC. Traumatic dislocation of the hip; a survey of two hundred and four cases covering a period of twenty-one years. *J Bone Joint Surg Am.* 1951;33-A(3):746–78.
- Wang SX, et al. Middle-term follow-up results of Pipkin type IV femoral head fracture patients treated by reconstruction plate and bioabsorbable screws. *Chin J Traumatol.* 2018;21(3):170–5.
- Harris WH. Traumatic arthritis of the hip after dislocation and acetabular fractures: treatment by mold arthroplasty. An end-result study using a new method of result evaluation. *J Bone Joint Surg Am.* 1969;51(4):737–55.
- Matta JM. Operative treatment of acetabular fractures through the ilioinguinal approach. A 10-year perspective. *Clin Orthop Relat Res.* 1994;305:10–9.
- Brooker AF, et al. Ectopic ossification following total hip replacement. Incidence and a method of classification. *J Bone Joint Surg Am.* 1973;55(8):1629–32.
- Ficat P, Arlet J. Etiopathogenesis of arthrosis; nosological consequences. *Rev Rhum Mal Osteoartic.* 1977;44(11):627–31.
- Asghar FA, Karunakar MA. Femoral head fractures: diagnosis, management, and complications. *Orthop Clin North Am.* 2004;35(4):463–72.
- Zelken JA. First-person long-term follow-up using autologous mosaicplasty for osteochondral lesion accompanying femoral head fracture. *J Orthop Trauma.* 2016;30(2):e70–4.
- Ahmed G, et al. Late versus early reduction in traumatic hip dislocations: a meta-analysis. *Eur J Orthop Surg Traumatol.* 2017;27(8):1109–16.
- Crock HV. An atlas of the arterial supply of the head and neck of the femur in man. *Clin Orthop Relat Res.* 1980;152:17–27.
- Ricci WM, et al. Open reduction and internal fixation of the femoral head via the smith-petersen approach. *J Orthop Trauma.* 2018;32(Suppl 1):S16–7.
- Gautier E, et al. Anatomy of the medial femoral circumflex artery and its surgical implications. *J Bone Joint Surg Br.* 2000;82(5):679–83.
- Guo JJ, et al. Impact of surgical approach on postoperative heterotopic ossification and avascular necrosis in femoral head fractures: a systematic review. *Int Orthop.* 2010;34(3):319–22.
- Ganz R, et al. Surgical dislocation of the adult hip a technique with full access to the femoral head and acetabulum without the risk of avascular necrosis. *J Bone Joint Surg Br.* 2001;83(8):1119–24.
- Massè A, et al. Surgical hip dislocation is a reliable approach for treatment of femoral head fractures. *Clin Orthop Relat Res.* 2015;473(12):3744–51.
- Solberg BD, Moon CN, Franco DP. Use of a trochanteric flip osteotomy improves outcomes in Pipkin IV fractures. *Clin Orthop Relat Res.* 2009;467(4):929–33.
- Ebraheim NA, et al. Sliding trochanteric osteotomy in acetabular fractures: a review of 30 cases. *Injury.* 2007;38(10):1177–82.
- Siebenrock KA, et al. Surgical dislocation of the femoral head for joint debridement and accurate reduction of fractures of the acetabulum. *J Orthop Trauma.* 2002;16(8):543–52.
- Sink EL, et al. Multicenter study of complications following surgical dislocation of the hip. *J Bone Joint Surg Am.* 2011;93(12):1132–6.
- Ellis TJ, Beck M. Trochanteric osteotomy for acetabular fractures and proximal femur fractures. *Orthop Clin North Am.* 2004;35(4):457–61.
- Helms JR, Nowotarski PJ. Posterior wall acetabulum fracture-dislocation with subsequent ipsilateral pipkin IV fracture-dislocation: how many hips can a hip take? *Trauma Case Rep.* 2015;1(9–12):65–72.
- Yu YH, et al. Surgical treatment for Pipkin type IV femoral head fracture. *J Orthop Surg (Hong Kong).* 2017;25(1):2309499016684970.
- Oransky M, et al. Fractures of the femoral head: a long-term follow-up study. *Musculoskelet Surg.* 2012;96(2):95–9.
- Brumback RJ, Kenzora JE, Levitt LE, Burgess AR, Poka A. Fractures of the femoral head. *Hip.* 1987;181–206. PMID: 3546215.

## Publisher's note

Springer Nature remains neutral with regard to jurisdictional claims in published maps and institutional affiliations.

### Ready to submit your research? Choose BMC and benefit from:

- fast, convenient online submission
- thorough peer review by experienced researchers in your field
- rapid publication on acceptance
- support for research data, including large and complex data types
- gold Open Access which fosters wider collaboration and increased citations
- maximum visibility for your research: over 100M website views per year

At BMC, research is always in progress.

Learn more [biomedcentral.com/submissions](https://biomedcentral.com/submissions)

