

CASE REPORT

Open Access



# Non-obstructed supracardiac total anomalous pulmonary venous connection with giant superior vena cava aneurysm

Yangbo Yan, Kai Yu, Yanlin Yang and Changping Gan\*

## Abstract

**Background:** Giant superior vena cava (SVC) aneurysm in non-obstructed supracardiac total anomalous pulmonary venous connection (TAPVC) is even more rare than in obstructed one, and this combination has not been reported.

**Case presentation:** Here we reported a 29-year-old young lady with non-obstructed TAPVC complicated with a giant SVC aneurysm. Routine TAPVC correction and tricuspid valve repair were done. Additionally, venectomy was carried out to seek for its histological etiology and to avoid potential complications.

**Conclusions:** If confirmed by further and larger experiences, for patients with non-obstructed supracardiac TAPVC with giant SVC aneurysm, surgical treatment of SVC aneurysm could be more aggressive to prevent cardiovascular complications.

**Keywords:** Total anomalous pulmonary venous connection, Superior vena cava, Aneurysm

## Background

Giant superior vena cava (SVC) aneurysm in obstructed supracardiac total anomalous pulmonary venous connection (TAPVC) is not a common congenital disease as reported [1–3]. A giant SVC aneurysm in non-obstructed TAPVC is more rare. Here we reported a 29-year-old female patient with non-obstructed TAPVC complicated with a giant SVC aneurysm.

## Case presentation

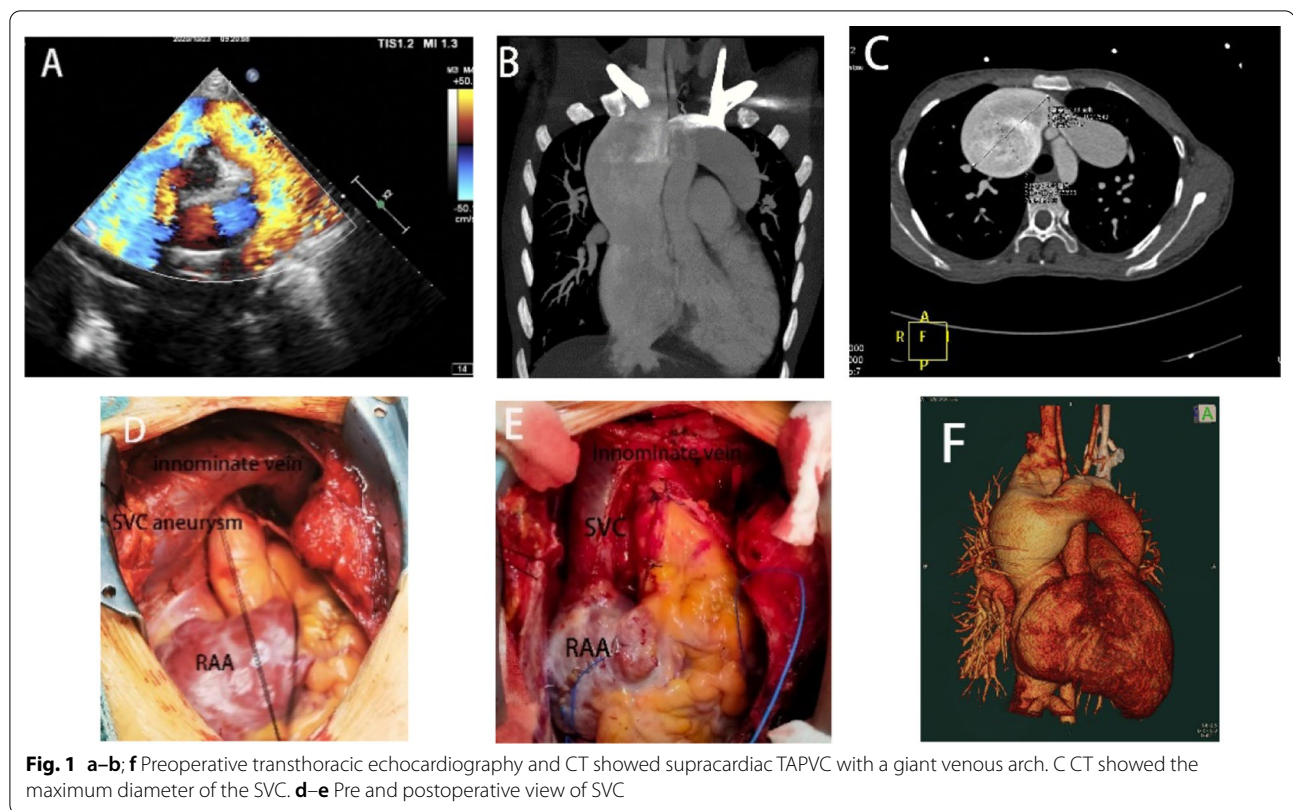
We saw the patient in the clinic due to her dyspnea and impaired exercise tolerance. She looked emaciated and her Body Mass Index (BMI) was only 14.62 kg/m<sup>2</sup>. Her cardiac function was graded NYHAII according to the history. Echocardiography and computed tomography (CT) before the operation confirmed the diagnosis of supracardiac TAPVC with a giant venous arch, which

were complicated with a 22 mm atrial septal defect (ASD) (Fig. 1a–b; f). The maximum diameter of the SVC was measured 7.68 × 6.32 cm (Fig. 1c). No obstruction throughout the venous pathway was noted neither by the echocardiography nor the CT. Angiography was conducted and the mean pulmonary artery pressure was measured as 22 mmHg with low pulmonary resistance. Intraoperative findings were consistent with all preoperative diagnosis (Fig. 1d).

To set up the cardiopulmonary bypass, along with the routine inferior vena cava (IVC) cannulation, two separate venous catheters were inserted into the right brachiocephalic vein and the innominate vein respectively. TAPVC correction was conducted by anastomosing the posterior wall of left atrium with the pulmonary venous confluence and ligating the vertical vein. The ASD was repaired with a bovine pericardial patch and a 30 mm plastic ring (MC3 4900, Edwards Life Science, Irvine, California, USA) was implanted to complete the tricuspid annular plasty. Considering that such a giant SVC aneurysm presented in a non-obstructed environment, we thought it might have

\*Correspondence: ganchangping@hotmail.com  
Department of Cardiovascular Surgery, West China Hospital, Sichuan University, No.37 Guo Xue Alley, Chengdu 610041, China





its histological etiology and would take a higher risk of thrombosis and/or rupture. Therefore, a partial venectomy was reasonable. With the distal veins controlled, the wall of the aneurysm was partially resected, and the diameter of SVC was reduced to a normal size (Fig. 1e). Pathology of the SVC revealed desmoplasia with hyaline degeneration and calcification in the vascular wall and mucoid degeneration in the focal area. Postoperative course was uncomplicated and she was discharged on the seventh postoperative day.

### Discussion and conclusion

Giant SVC aneurysm in supracardiac total anomalous pulmonary venous connection (TAPVC) is rare, a few cases in obstructed TAPVC were reported. [1–3] However, no report about non-obstructed TAPVC with SVC aneurysm was published so far. In the present case, no obstruction throughout the venous pathway was noted while the aneurysm was too large to neglect.

Some literatures have concluded that, compared with a saccular shape, a fusiform SVC aneurysm will usually have a benign prognosis, thus no aggressive treatment is needed [1–4]. However, for saccular aneurysm of SVC, surgical treatment is more recommended to avoid or to treat the complications. With median sternotomy and cardiopulmonary bypass, the aneurysm is totally resected

in some publications [5–8]. While in other reports, the aneurysmatic sac is opened and removed, and then SVC is reconstructed with a pericardial patch [9, 10], or primarily sutured [11]. Thus, taking into consideration that the potentially histology-backgrounded aneurysm would increase the risk of cardiovascular complications, the angioplasty for SVC was done as above-mentioned. The result of pathology also implied her risk factors of cardiovascular diseases.

In spite of the insufficient literature in this area, the treatment for SVC aneurysm could be more aggressive to prevent cardiovascular complications in patients with non-obstructive supracardiac TAPVC with giant SVC aneurysm.

### Abbreviations

TAPVC: Total anomalous pulmonary venous connection; SVC: Superior vena cava; TVP: Tricuspid valvuloplasty; BMI: Body Mass Index; CT: Computed tomography; IVC: Inferior vena cava; ASD: Atrial septal defect; RAA: Right atrial appendage.

### Acknowledgements

Authors would like to thank the patient for her kind participation and cooperation in our study.

### Authors' contributions

YY, KY, YY and CPG aided in data gathering and interpretation of results. YY, KY and YY aided in interpretation of results and preparation of manuscript. CPG

aided in critical revision of the final manuscript. All authors read and approved the final manuscript.

#### Funding

This study was partially supported by grants from the Science and Technology Department of Sichuan Province (2020YJ0239) and the Health Planning Committee of Sichuan Province (20PJ052). The funders had no role in the study design, data collection and analysis, writing of the manuscript, and decision to submit the article for publication.

#### Availability of data and materials

Not applicable.

#### Ethics approval and consent to participate

As this was a case report no institutional ethics committee approval was obtained and only written and informed consent was obtained from the patient for the publication of this study,

#### Consent to publish

Written informed consent was obtained from the patient for publication of this case report and any accompanying images. A copy of the written consent is available for review by the Editor of this journal.

#### Competing interest

There is no conflict of interest to be declared regarding the manuscript.

Received: 13 December 2020 Accepted: 4 March 2021

Published online: 17 March 2021

#### References

- Vida VL, Leon-Wyss J, Veras O, Vides I, Castaneda AR. Rare case of obstructive supracardiac total anomalous pulmonary venous connection in association with a giant superior vena cava. *Ann Thorac Surg*. 2006;81(3):1141.
- Tsai YS, Yu CH, Pang KK, Shih SL. A giant superior venous cava resulted from obstructive total anomalous pulmonary venous connection. *Circ Cardiovasc Imaging*. 2009;2(2):161–2.
- Thummar AC, Phadke MS, Lanjewar CP, Nabar AA, Kerkar PG. Supracardiac total anomalous pulmonary venous drainage with giant superior vena cava aneurysm: a rare combination. *J Am Coll Cardiol*. 2014;63(19):e51.
- Koga S, Ikeda S, Sanuki Y, Ninomiya A, Izumikawa T, Miyahara Y, Kohno S. A case of asymptomatic fusiform aneurysm of the superior vena cava detected by magnetic resonance imaging. *Int J Cardiol*. 2006;113(2):e39–41.
- Oh SG, Kim KH, Seon HJ, Yoon HJ, Ahn K, Jeong MH, Cho JG, Park JC, Kang JC. Unusual cause of acute right ventricular dysfunction: rapid progression of superior vena cava aneurysm complicated by thrombosis and pulmonary thromboembolism. *J Korean Med Sci*. 2011;26(5):690–3.
- Panduranga P, Thomas E, Al-Maskari S, Al-Farqani A. Giant superior vena caval aneurysm in a post-Glenn patient. *Interact Cardiovasc Thorac Surg*. 2012;14(6):878–9.
- Varma P, Dharan B, Ramachandran P, Neelakandhan K. Superior vena caval aneurysm. *Interactive Cardiovasc Thorac Surg*. 2003;2(3):331–3.
- Gozdziuk K, Czekajaska-Chehab E, Wrona A, Tomaszewski A, Drop A. Saccular aneurysm of the superior vena cava detected by computed tomography and successfully treated with surgery. *Ann Thorac Surg*. 2004 Dec;78(6):e94–5.
- Soares Souza LV, Souza AS, Morales MM, Marchiori E. Superior vena cava aneurysm: an unusual mediastinal mass. *Eur J Cardiothorac Surg*. 2021;59(1):276–277.
- Janczak D, Skiba J, Gemel M, Mak M, Ziomek A, Malinowski M, Dorobisz T, Lesniak M, Janczak D, Chabowski M. Giant saccular superior vena cava aneurysm—a rare and difficult clinical case. *J Thorac Dis*. 2016;8(3):E247–9.
- Yuan Y, Lu HJ. Giant superior vena cava aneurysm. *Eur J Vasc Endovasc Surg*. 2016;52(5):587.

#### Publisher's note

Springer Nature remains neutral with regard to jurisdictional claims in published maps and institutional affiliations.

Ready to submit your research? Choose BMC and benefit from:

- fast, convenient online submission
- thorough peer review by experienced researchers in your field
- rapid publication on acceptance
- support for research data, including large and complex data types
- gold Open Access which fosters wider collaboration and increased citations
- maximum visibility for your research: over 100M website views per year

At BMC, research is always in progress.

Learn more [biomedcentral.com/submissions](https://biomedcentral.com/submissions)

